

Calcifying Tendinitis Of The Shoulder

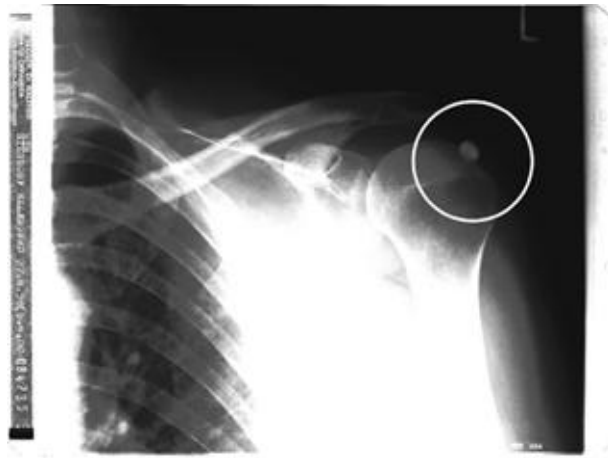By Dr. Med. Wolfram Haas, Spremlingen, Germany

The Situation

From February 2000 the female patient suffered from severe pain in the left shoulder that was unbearable at night. The patient needed the strongest painkillers in order to sleep for even a short time.

The orthopaedic specialist diagnosed a calcifying tendonitis of the left shoulder. Local injections with cortisone and painkillers provided little relief.

After 4 months of treatment surgery was recommended due to the persistent and intense pain.



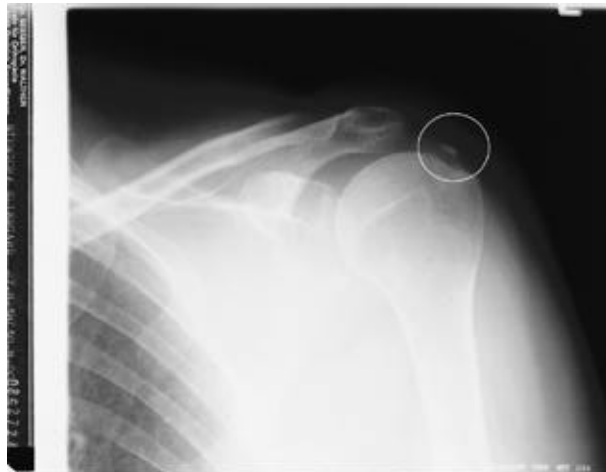Date of x-ray: 06 April 2000

Pain free with QRS within a short time

QRS therapy was applied by Dr. Med. W Hass, general practitioner. The pillow applicator was used for 16 minutes twice daily on setting 10. The results were:

- a. Day 7 - painkillers no longer required
- b. Day 8 - no pain while resting, including at night.
- c. Day 14 - 75% of the normal mobility range of the left arm was possible free of pain.
- d. Day 28 - Total mobility was achieved.

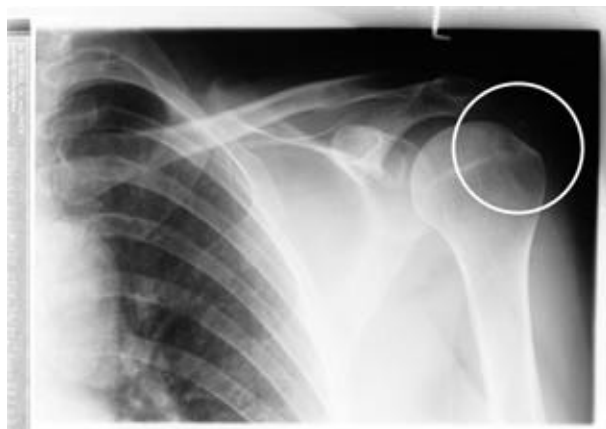
Date of x-ray: 30 August 2000



Movement of Calcium

The x-rays show the gentle, non-invasive, non-drug and yet rapid dissolving of the calcium deposit over a period of six months. Two hydrogen ions ($2H^+$) have replaced the negative charges bonding to the calcium. The calcium, in its ionized form (Ca^{++}), then moves through the intercellular fluids to cells that require calcium or it is carried to waste.

This simply study has implications for people with calcium plaque deposits on the walls of blood vessels—a major cause of heart disease. QRS will dissolve this calcium relatively slowly and gently.



Date of x-ray: 31 October 2000